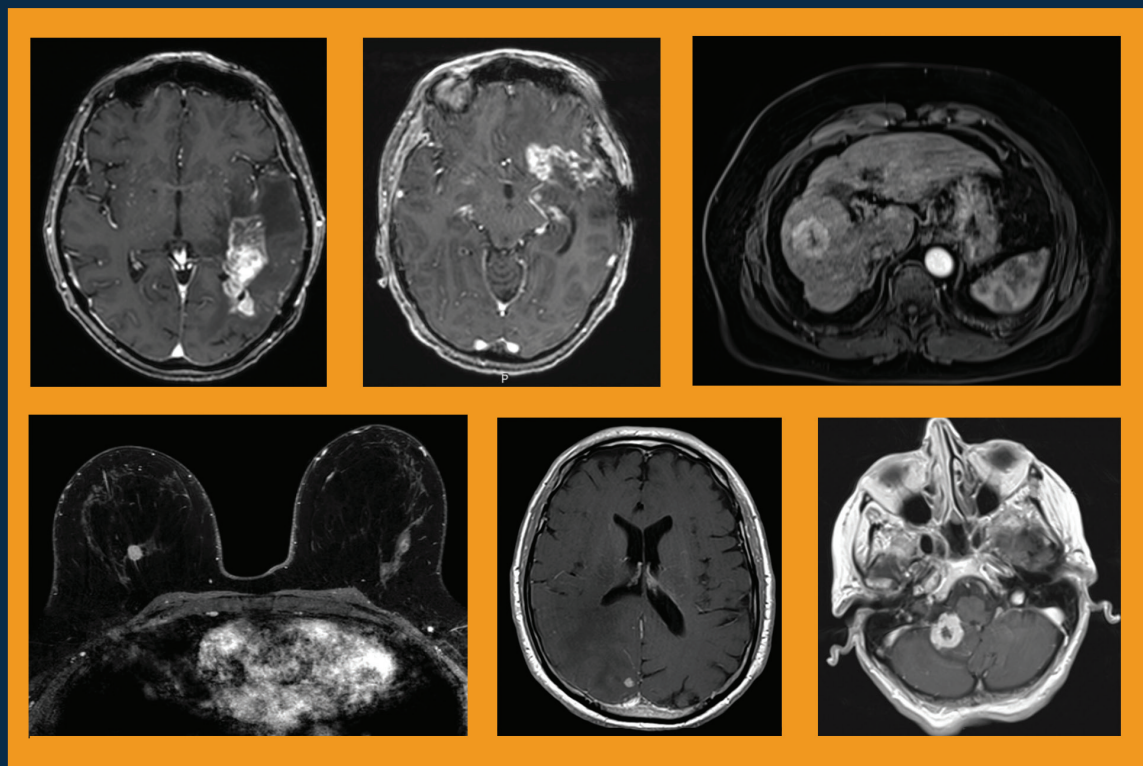


AppliedRadiology[®]

The Journal of Practical Medical Imaging and Management

Development and Use of Elucirem[™] (gadopiclenol) Injection, a Macrocyclic, High-relaxivity GBCA for CE-MRI



Supported by Guerbet

Applied Radiology®

The Journal of Practical Medical Imaging and Management

Anderson Publishing, Ltd
180 Glenside Avenue,
Scotch Plains, NJ 07076
Tel: 908-301-1995
Fax: 908-301-1997
info@appliedradiology.com

PRESIDENT & CEO

Oliver Anderson

GROUP PUBLISHER

Kieran N Anderson

EDITOR-IN-CHIEF

Erin Simon Schwartz, MD, FACR

EXECUTIVE EDITOR

Joseph F Jalkiewicz

PRODUCTION

Barbara A Shopiro

View more information about Elucirem™



GU01230001

©2023 Anderson Publishing, Ltd. All rights reserved.
Reproduction in whole or in part without written
permission is strictly prohibited. USPS: 0943-180

Development and Use of Elucirem™ (gadopiclenol) Injection, a Macrocyclic, High-relaxivity GBCA for CE-MRI

Faculty



Lawrence Tanenbaum, MD, FACR
Chief Technology Officer
Director of Advanced Imaging
Vice President, RadNet Inc.




Laurie A. Loevner, MD
Division Chief, Neuroradiology
Perelman School of Medicine at
the University of Pennsylvania



Donna Roberts, MD
Professor of Radiology
Medical University of South Carolina



Jeffrey Weinreb, MD
Chief, Radiology Services
Director of MRI Services
Yale New Haven Hospital



Ahmed Abdelal, PharmD
Global Head of Medical II
NA Head of MA & RA
Medical & Regulatory Affairs
Guerbet Group

Program Description

After decades of administrations, substantial evidence has accumulated for the efficacy and safety of gadolinium-based contrast agents (GBCAs) in magnetic resonance imaging (MRI). However, their excellent performance has led to increased use and dosing for many neuro and cardiovascular applications in adults and children.

As a result, concern has been growing in the radiology community, particularly with respect to use of the less stable agents, which are generally linear and, therefore, bind less tightly to the gadolinium (Gd) ion. While recognizing the value of these agents, the US Food and Drug Administration (FDA) and the American College of Radiology (ACR) now recommend limiting patient Gd exposure where possible.

One technique for reducing Gd exposure is to use a high-relaxivity GBCA that can be used at a lower dose than a conventional GBCA without impact on image quality. Until recently, however, the GBCA with the highest relaxivity was a linear agent. Consequently, it has been widely recognized for some time that it would be preferable if a GBCA was both macrocyclic in structure and high relaxivity, and that such an agent could be used to reduce Gd exposure by decreasing the amount of Gd injected.

A new GBCA that is both macrocyclic and high relaxivity has been developed and received FDA marketing approval in September 2022. A group of radiologists with extensive experience in contrast-enhanced (CE)-MRI convened to discuss this new GBCA, Elucirem™ (gadopiclenol) injection, and this monograph presents a summary of this expert panel forum.

Learning Objectives

At the conclusion of this activity, participants should be able to:

- Describe the properties that distinguish Elucirem from the other high-relaxivity and conventional GBCAs;
- Demonstrate an understanding of the clinical development program of Elucirem for neuro and body imaging;
- Define the patient populations that are most vulnerable to higher and/or repeat dosing of GBCAs; and,
- Explain the factors to be considered when deciding to use MRI contrast in vulnerable patient populations.

Target Audience

- Radiologic Technologists
- Radiology Administrators
- Related Imaging Professionals

Instructions

Participants must complete this activity during the accreditation period and follow these instructions.

1. Review this article in its entirety.
2. Visit <https://www.appliedradiology.org/7a>
3. Log in or create an account.
4. Add activity to your account.
5. Complete the posttest.
6. Complete the evaluation.
7. Print your certificate

Accreditation Period

Release: February 24, 2023 **Expiration:** March 31, 2026 **Time:** 1 hour

Accreditation

This article confers 1.0 ARRT Category A Continuing Education credit, which will be awarded upon completion of an online posttest. The entire text of this supplement, learning objectives, and the posttest are available at <https://www.appliedradiology.org/7a>.

Commercial Support

This content is supported by Guerbet.

Development and Use of Elucirem™ (gadopiclenol) Injection, a Macrocyclic, High-relaxivity GBCA for CE-MRI

Introduction

The use of gadolinium-based contrast agents (GBCAs) in magnetic resonance imaging (MRI) has been extensively researched, and substantial evidence of their efficacy and safety has accumulated over the past several decades.¹ Clinical trials and radiology practices have demonstrated that GBCAs enhance the sensitivity, specificity, and diagnostic confidence of MRI, as well as improve reliability and shorten examination times, leading to increased usage and dosing for various neuro and cardiovascular applications in both adult and pediatric patients. However, there has been growing concern among the radiology community regarding the less stable, linear GBCAs, which bind less tightly to the Gd ion.² In light of the value of contrast for MRI, the Food and Drug Administration (FDA) and the American College of Radiology (ACR) now recommend limiting patient exposure to Gd where possible.^{1,3} One solution to reduce exposure is the use of high-relaxivity GBCAs, which can be administered at lower doses without affecting image quality. Until recently, the highest-relaxivity GBCA was a linear agent,⁴ leading to the recognition that it would be preferable for a GBCA to be both macrocyclic in structure and high in relaxivity, thus reducing the amount of Gd injected and exposure to patients.

A novel macrocyclic and high-relaxivity GBCA, Elucirem™ (gadopiclenol) injection, has been developed and received FDA approval in September 2022. An expert panel of radiologists with extensive CE-MRI experience convened to evaluate the development and utilization of this new GBCA. This monograph represents a summary of the expert panel forum.

ELUCIREM™ (gadopiclenol) injection Important Safety Information

WARNING: NEPHROGENIC SYSTEMIC FIBROSIS (NSF)

See full prescribing information for complete boxed warning

Gadolinium-based contrast agents (GBCAs) increase the risk for NSF among patients with impaired elimination of the drugs. Avoid use of GBCAs in these patients unless the diagnostic information is essential and not available with non-contrast MRI or other modalities.

- The risk for NSF appears highest among patients with:
 - Chronic, severe kidney disease (GFR <30 mL/min/1.73 m²), or
 - Acute kidney injury.
- Screen patients for acute kidney injury and other conditions that may reduce renal function. For patients at risk for chronically reduced renal function (for example, age >60 years, hypertension or diabetes), estimate the glomerular filtration rate (GFR) through laboratory testing.

Please see additional safety information at the end of this article, page 14.

Gadolinium-based Contrast Agents

Several GBCAs are approved for use in the United States.⁵⁻¹² (Table 1) The oldest of these were approved in the early 1990s, and the most recent were approved in 2022. All consist of a Gd ion chelated to a ligand, and it is the molecular structure of this ligand that determines the unique efficacy and safety profile of each agent.

GBCA Ligand Structure and Stability

The ligand that binds the potentially toxic Gd ion can be linear or macrocyclic, and ionic or nonionic. These properties largely determine the stability of the Gd-ligand chelate which, in turn, affects the likelihood of the chelate to release free Gd.¹³ In general, the linear, nonionic GBCAs have lower stability than do the macrocyclic, ionic GBCAs.^{13,14}

The significance of GBCA stability cannot be overstated. In 2006, lower-stability GBCAs were found to be associated with the development of nephrogenic systemic fibrosis (NSF).¹⁵ This sometimes-fatal systemic fibrosing disorder developed almost exclusively in patients with severe renal dysfunction who had received multiple and/or higher doses of Omniscan, OptiMARK® (gadoversetamide), or Magnevist® (gadopentetate dimeglumine); the latter two of which have been discontinued.¹ This led the American College of Radiology to classify GBCAs according to their NSF risk. (Table 2)

Although the pathophysiologic mechanism of NSF is not completely understood, the longer half-life of GBCAs in patients unable to eliminate them via renal excretion, coupled with the lower stability of the high-risk GBCAs, is believed to

Table 1. Currently Available GBCAs⁵⁻¹²

Trade Name*	Generic Name	Structure	Ionicity	FDA Approval Date
ProHance®	Gadoteridol	Macrocylic	Nonionic	1992
Omniscan™	Gadodiamide	Linear	Nonionic	1993
MultiHance®	Gadobenate dimeglumine	Linear	Ionic	2004
Gadavist®	Gadobutrol	Macrocylic	Nonionic	2011
Dotarem™†	Gadoterate meglumine	Macrocylic	Ionic	2013
Clariscan™†	Gadoterate meglumine	Macrocylic	Ionic	2019
Elucirem™§	Gadopiclenol	Macrocylic	Nonionic	2022
Vueway™§	Gadopiclenol	Macrocylic	Nonionic	2022

*Magnevist® (gadopentetate dimeglumine) and OptiMARK® (gadoversetamide) have been discontinued.
 †Dotarem® and Clariscan® have the equivalent active pharmaceutical ingredient.
 §Elucirem™ and Vueway™ have the equivalent active pharmaceutical ingredient.

Table 2. American College of Radiology Classification of GBCAs by NSF Risk¹

Group I: Agents associated with the greatest number of NSF cases:
Gadodiamide (Omniscan™ – GE Healthcare)
Gadopentetate dimeglumine (Magnevist® – Bayer HealthCare Pharmaceuticals)
Gadoversetamide (OptiMARK® – Guerbet)
Group II: Agents associated with few, if any unconfounded cases of NSF:
Gadobenate dimeglumine (MultiHance® – Bracco Diagnostics)
Gadobutrol (Gadavist® – Bayer HealthCare Pharmaceuticals)
Gadoteric acid (Dotarem® - Guerbet; Clariscan™ – GE Healthcare)
Gadoteridol (ProHance® – Bracco Diagnostics)
Group III: Agents for which data remain limited regarding NSF risk, but for which few, if any, unconfounded cases of NSF have been reported:
Gadoxetate disodium (Eovist® – Bayer HealthCare Pharmaceuticals)

*Magnevist® (gadopentetate dimeglumine) and OptiMARK® (gadoversetamide) have been discontinued; Elucirem and Vueway have yet to be classified by the ACR.

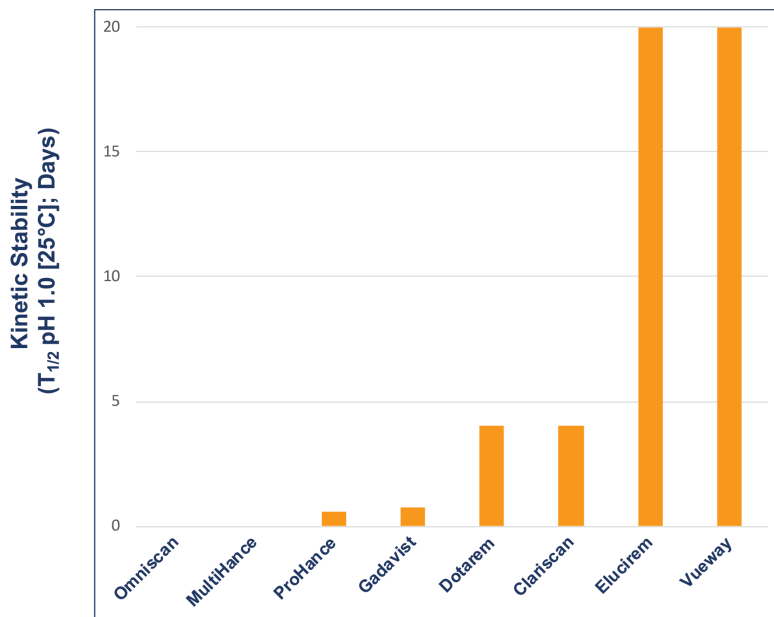
lead to the dermal fibrosis associated with NSF.² In support of this hypothesis, Gd has been detected in the skin of patients with NSF.¹⁶ Changes in practice (eg, screening at-risk patients, using more stable agents) have greatly reduced the risk for NSF, with very few cases still being reported.

Even before concerns were raised over NSF, Gd was known to accumulate in the bones and organs of GBCA recipients.^{17,18} Years later, many publications demonstrated contrast enhancement in noncontrast scans of the brain in patients who had previously received a GBCA.¹⁹⁻²³ Although this enhancement was seen primarily in patients

who had received a linear GBCA, very sensitive analysis revealed Gd in brain tissue following administration of all GBCAs, regardless of whether they were linear or macrocyclic.²⁴ Consequences of gadolinium retention in the brain have not been established; however, the potential for Gd to accumulate in the body is clearly not desirable, particularly in young patients and/or those who require frequent surveillance MRI exams with contrast.

The precise stability of GBCAs is measurable *in vitro* and is typically represented by the conditional thermodynamic and kinetic stability constants. The conditional thermodynamic stability constant

Figure 1. Kinetic stability of the currently available GBCAs (measured in biologic medium).⁴



can be thought of as depicting *how much* Gd is released, and the kinetic stability constant as *how fast* Gd is released.^{13,14} The kinetic stability constant is perhaps the more important of the two; if dissociation is slow enough, GBCA elimination is likely to occur before dissociation. Figure 1 shows the kinetic stability constant for each of the available GBCAs: the constants are higher for the macrocyclic GBCAs.⁴ Notably, the constant of the new macrocyclic GBCA, gadopiclenol, is much higher than that of the other macrocyclic agents, indicating that the new agent has a higher dissociation half-life compared to the other GBCAs.⁴

GBCA Relaxivity

Relaxivity is the property that most relates to the efficacy of a GBCA: the higher the relaxivity, the greater signal-to-noise that will be produced on MR images. All GBCAs had comparable relaxivity until 2004, when MultiHance, a higher-relaxivity GBCA received FDA approval. MultiHance possesses high relaxivity owing to its ability

to bind to protein, specifically albumin, which increases the effective molecular weight and slows the molecular tumbling, resulting in higher relaxivity.²⁵ As a result, MultiHance possesses at least twice the relaxivity of conventional GBCAs.⁴ (Table 3) Many randomized, inpatient, crossover trials comparing MultiHance with conventional GBCAs for a wide array of applications showed that, at equivalent Gd doses, MultiHance enhanced significantly more brightly.²⁶⁻⁴⁰ In addition, many similarly designed studies showed that at half the Gd dose, MultiHance provided enhancement equivalent to a full dose of a conventional GBCA.⁴¹⁻⁴⁷ The ability to obtain brighter enhancement or, alternatively, to use lower doses, provided a breakthrough in flexibility for contrast-enhanced MRI (CE-MRI).

Because MultiHance is linear, many radiologists who had moved toward macrocyclic agents for safety reasons have been reserving it for certain niche applications where the higher relaxivity may be of particular benefit. There

has clearly been a need for a highly stable, macrocyclic agent with high relaxivity that could be used to increase contrast or reduce Gd dose.

In 2022, the FDA approved Elucirem, the first high-relaxivity, macrocyclic GBCA with 2 water molecule exchange sites. In contrast to MultiHance, Elucirem achieves higher relaxivity via a different mechanism: a greater hydration number. Elucirem is capable of binding to two water nuclei ($q=2$), while all other GBCAs bind only one ($q=1$).⁴ Interaction with this greater number of water molecules results in higher relaxivity. In fact, as shown in Table 3, the relaxivity of Elucirem is approximately twice that of MultiHance and four times that of conventional GBCAs.⁴

Tolerability of GBCAs

Millions of doses of GBCAs have been administered worldwide, providing ample evidence of their excellent safety profile and very low rate of adverse reactions (0.07% to 2.4%).^{1,48} Most side effects are mild and allergic or physiologic, with hives, nausea, and vomiting the most commonly reported.¹ Severe adverse events are exceedingly rare (0.001% to 0.01%).⁴⁹ Moreover, small differences in adverse event rates among GBCAs have been demonstrated in large-scale analyses, with the linear, nonionic GBCAs demonstrating a slightly lower incidence of adverse events.^{49,50}

GBCA Indications and Dosing

Most GBCAs are formulated at 0.5 M, indicated at the standard 0.1 mmol/kg dose in adults and children over the age of 2 years, and approved for a variety of neuro and body indications. An exception is Gadavist, which is formulated at 1 M.⁸ Given the concerns over Gd exposure, the clinical development program

of Elucirem focused not on using this high-relaxivity GBCA to further increase contrast enhancement, but rather on using it at half dose to reduce Gd exposure. Therefore, Elucirem is approved at 0.05 mmol/kg for adult and pediatric patients over age 2 years to detect and visualize lesions with abnormal vascularity in the central nervous system (brain, spine, and associated tissues) and the body (head and neck, thorax, abdomen, pelvis, and musculoskeletal system).⁷

Elucirem in Adult MR Neuroimaging

For the vast majority of adult neuroimaging applications, contrast is deemed necessary, and a conventional GBCA is considered sufficient. The potential to utilize Elucirem at the approved 0.05 mmol/kg dose and thereby reduce patient exposure to Gd is in line with health agency recommendations. Specifically, the FDA recommends “limiting GBCA dosing and allowing for adequate GBCA clearance between doses.”⁷³ The agency also added a recommendation to the black box warning for all GBCAs to “avoid use of GBCAs in these (at-risk) patients unless the diagnostic information is essential and not available with noncontrast MRI or other modalities.”⁷⁵⁻¹² Such at-risk patients include those with impaired elimination of drugs attributable to severe chronic kidney disease or acute kidney injury.

The ACR, meanwhile, recommends that “the lowest dose of GBCA required to obtain the needed clinical information ... be used in at-risk patients, and it should generally not exceed the recommended single dose.”⁷¹ Reduced Gd exposure is particularly important in children, patients with renal impairment, and those requiring routine surveillance

Table 3. Relaxivity of Currently Available GBCAs*

Trade Name	Kinetic Stability ($T_{1/2}$ pH 1.0 [25°C])	r1 at 1.5T ($\text{mM}^{-1}\text{s}^{-1}$ [37°C])	r2 at 3T ($\text{mM}^{-1}\text{s}^{-1}$ [37°C])
Omniscan™	< 5 sec	4.3	4.0
ProHance®	4 hr	4.1	3.7
Gadavist®	18 hr	5.2	5.0
Dotarem™	4 days	3.6	3.5
Clariscan™	4 days	3.6	3.5
MultiHance®	NA	6.3	5.5
Elucirem™	20 days	12.8	11.6
Vueway™	20 days	12.8	11.6

*Measured in biological medium.

with CE-MRI; eg, patients with multiple sclerosis, where cumulative doses can become quite high over the patient’s lifetime.

Elucirem Clinical Development Program for Neuroimaging

A Phase 2b international, multicenter, double-blind, randomized, controlled, parallel-dose groups, crossover study was performed in 272 adult subjects with known or highly suspected lesions with a disrupted blood-brain barrier, including at least one previously detected enhancing lesion.⁵¹ Patients were randomized to 1 of 4 doses of gadopiclenol (0.025, 0.05, 0.1, 0.2 mmol/kg) and to 1 series of 2 MRI scans: gadopiclenol then MultiHance (gadobenate dimeglumine) 0.1 mmol/kg, or vice versa. The qualitative and quantitative efficacy evaluations were performed by 3 independent off-site blinded readers. Adverse events were monitored up to 1 day after the 2nd MRI.

The results showed that the relationship between CNR and the gadopiclenol dose was linear for all readers. Compared with MultiHance at 0.1 mmol/kg, the gadopiclenol doses of 0.05 and 0.1 mmol/kg gave similar or significantly greater contrast enhancement, respectively. Thus,

the authors concluded that both doses could be considered for future phase 3 studies. However, as mentioned, the Elucirem clinical development program focused not on using this high-relaxivity GBCA to further increase contrast enhancement, but rather on using it at half the conventional dose to reduce Gd exposure.

As part of the phase 3 trial, gadopiclenol-enhanced images were compared to unenhanced images and to Gadavist (gadobutrol)-enhanced images for MRI of the brain in 256 subjects (the PICTURE Trial; NCT03996447).^{7,52} The primary objectives were to demonstrate that Elucirem at 0.05 mmol/kg was superior to unenhanced MRI and noninferior to Gadavist at 0.1 mmol/kg. Lesion visualization parameters (border delineation, internal morphology, and degree of contrast enhancement) were assessed by 3 independent blinded readers. Up to 3 of the most representative brain lesions were scored for each parameter (from 1 to 4: 1 = none/poor, 2 = moderate, 3 = good, 4 = excellent), and the mean score was calculated. The main inclusion criteria were female or male adult with known CNS lesion(s) detected on a previous imaging study. The study design was a prospective, double-blinded,

Figure 2. Study design of the PICTURE Trial.^{7,52}

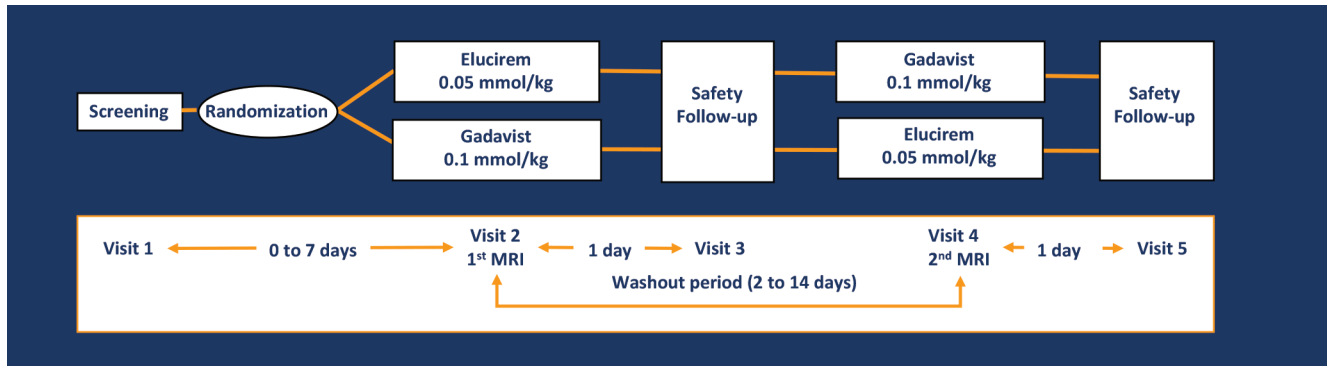


Figure 3. Comparison of lesion visualization between unenhanced and Elucirem-enhanced paired brain MR images demonstrating significantly (* $P < 0.001$) better lesion visualization with Elucirem.^{7,52}

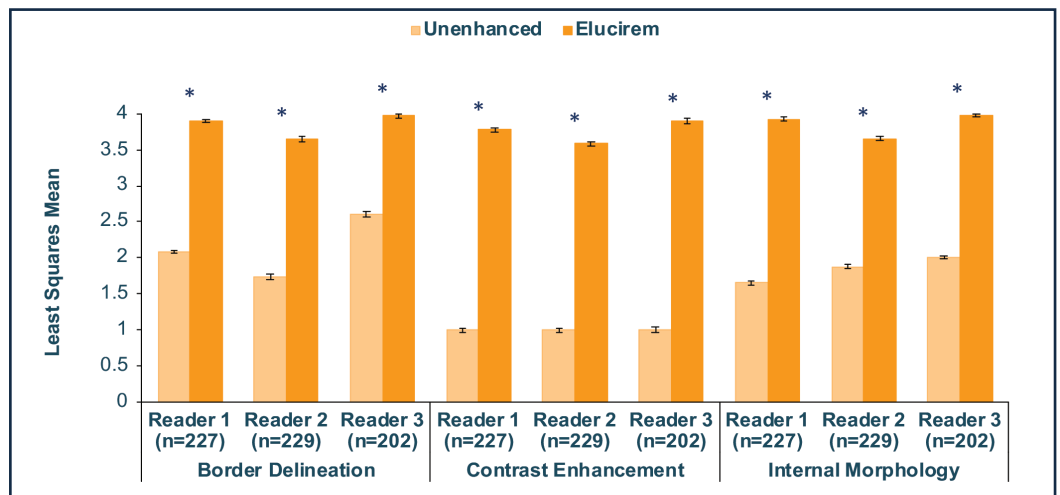
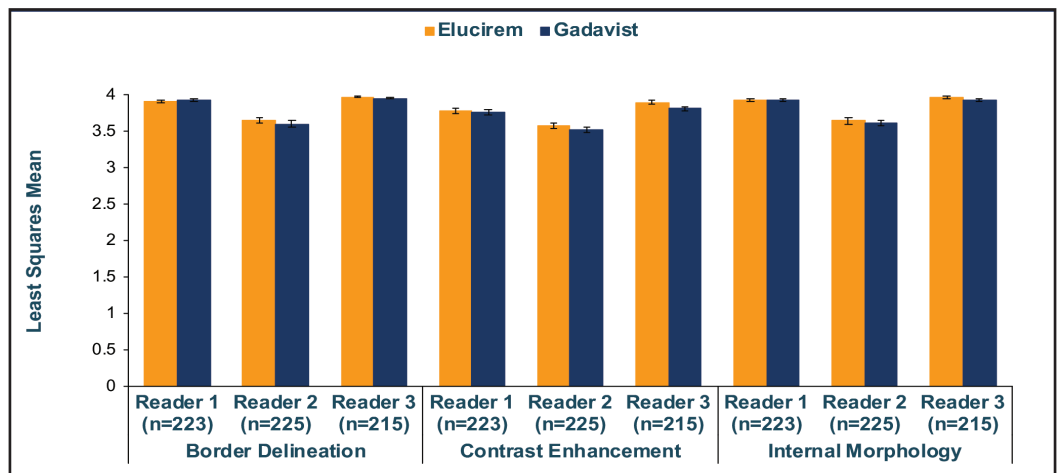


Figure 4. Comparison of lesion visualization between 0.05 mmol/kg Elucirem-enhanced and 0.1 mmol/kg Gadavist-enhanced paired brain MR images demonstrating noninferiority of Elucirem (lower limit of the 95% CI of the difference above the noninferiority margin of -0.35 in all cases [$P < 0.0001$]).^{7,52}



randomized, comparative, multicenter, controlled, cross-over study.^{7,52} (Figure 2) The trial disease diagnoses included meningiomas (32.1%), brain metastases (22.9%), and glial tumors (21.7%).⁵³

Qualitative and quantitative results are shown in Figures 3-6.^{7,52} In terms of lesion visualization, Elucirem-enhanced MRI was shown to be significantly superior to unenhanced MRI for all 3

parameters for all 3 readers. (Figure 3) Gadopiclenol was also shown to be noninferior to Gadavist for all 3 visualization parameters for all 3 readers. (Figure 4) In the PICTURE Trial, overall diagnostic preference

Figure 5. Comparison of overall diagnostic preference between 0.05 mmol/kg Elucirem-enhanced and 0.1 mmol/kg Gadavist-enhanced paired brain MR images demonstrating Elucirem-enhanced images were preferred in majority to Gadavist-enhanced images.^{7,52}

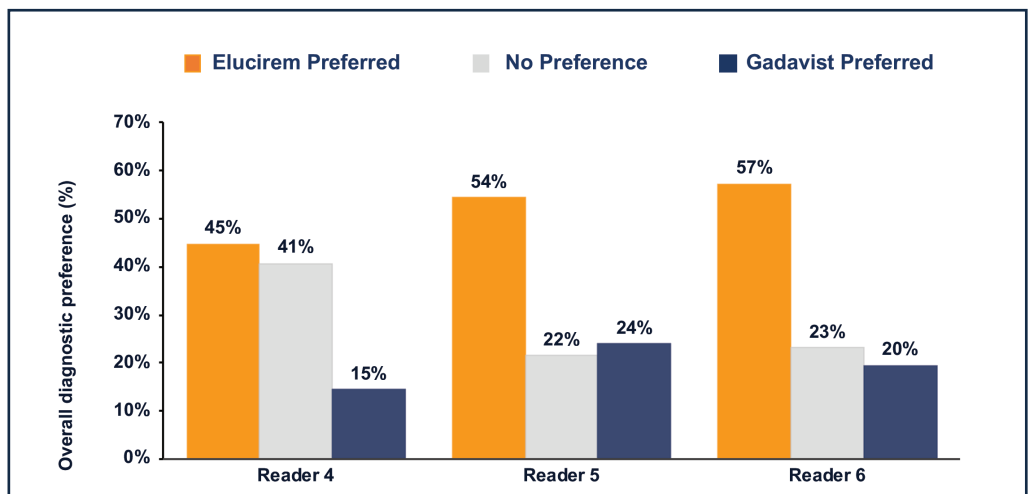
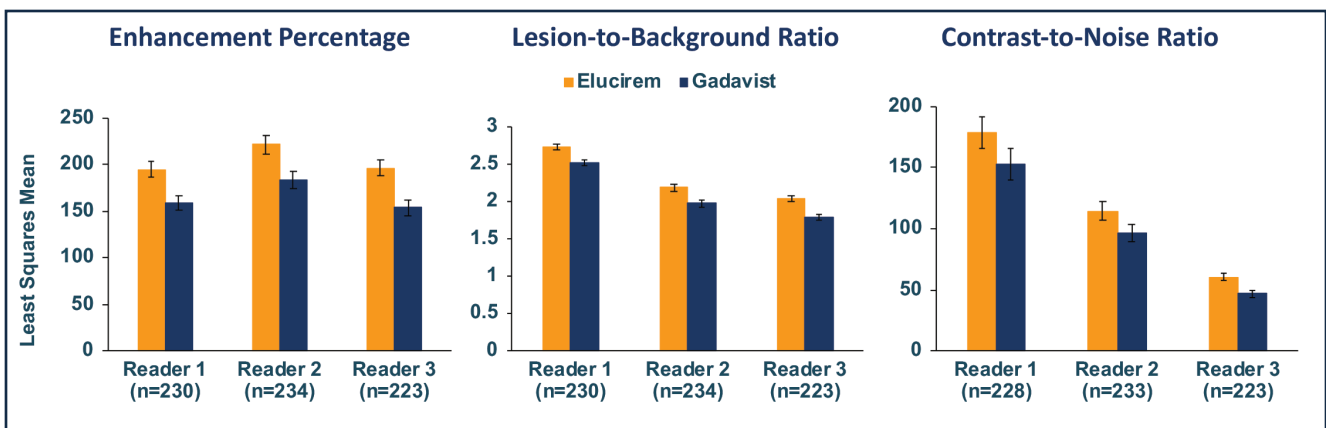


Figure 6. Comparison of enhancement percentage (E%), lesion-to-background ratio (LBR), and contrast-to-noise ratio (CNR) between 0.05 mmol/kg Elucirem-enhanced and 0.1 mmol/kg Gadavist-enhanced paired images demonstrating E% and LBR were significantly higher with Elucirem for all 3 readers ($P < 0.0001$) and CNR was significantly higher with Elucirem for 2 readers ($P < 0.0001$, $P = 0.0182$).^{7,52}



was assessed by 3 other independent blinded readers in a global matched-pairs fashion, and images with gadopiclenol at 0.05 mmol/kg were preferred to images with Gadavist at 0.1 mmol/kg by all 3 readers. (Figure 5)

The assessed quantitative parameters included enhancement percentage (E%), lesion-to-background ratio (LBR), and contrast-to-noise ratio (CNR). For gadopiclenol at 0.05 mmol/kg, E% and LBR were significantly higher for all 3 readers ($P < 0.0001$), and CNR was significantly higher with gadopiclenol for 2 of 3 readers ($P < 0.0001$ and $P = 0.0182$). (Figure 6) Examples of results from two patients enrolled

in the PICTURE Trial are shown in Figures 7 and 8.⁵²

Safety results from the PICTURE Trial demonstrated that gadopiclenol has a good safety profile, comparable to Gadavist. Post-injection treatment emergent adverse events (TEAEs) were reported in 14.6% of subjects after gadopiclenol administration and 17.6% of patients after Gadavist administration.^{7,52} Of those considered contrast related, 4.9% of subjects reported an adverse event after gadopiclenol and 6.9% after Gadavist. Most TEAEs were mild (94.2%).^{7,52} The most common adverse events with both GBCAs were injection site reactions.^{7,52} No safety concerns were detected regarding laboratory results

and vital signs, and no cases of NSF were reported.^{7,52}

In summary, phase 2 and phase 3 studies demonstrated that for neuroimaging, the higher relaxivity of Elucirem could be used safely to reduce Gd exposure in patients without reducing the qualitative or quantitative efficacy one would expect from a contrast-enhancing GBCA.

Elucirem in Body MR Imaging

In addition to neuroimaging, many body imaging applications require contrast, and the vast majority of radiology practices use a conventional GBCA. However, higher relaxivity may be beneficial

Figure 7. Matched pair of brain MR images from a 65-year-old male with brain metastases.⁵²

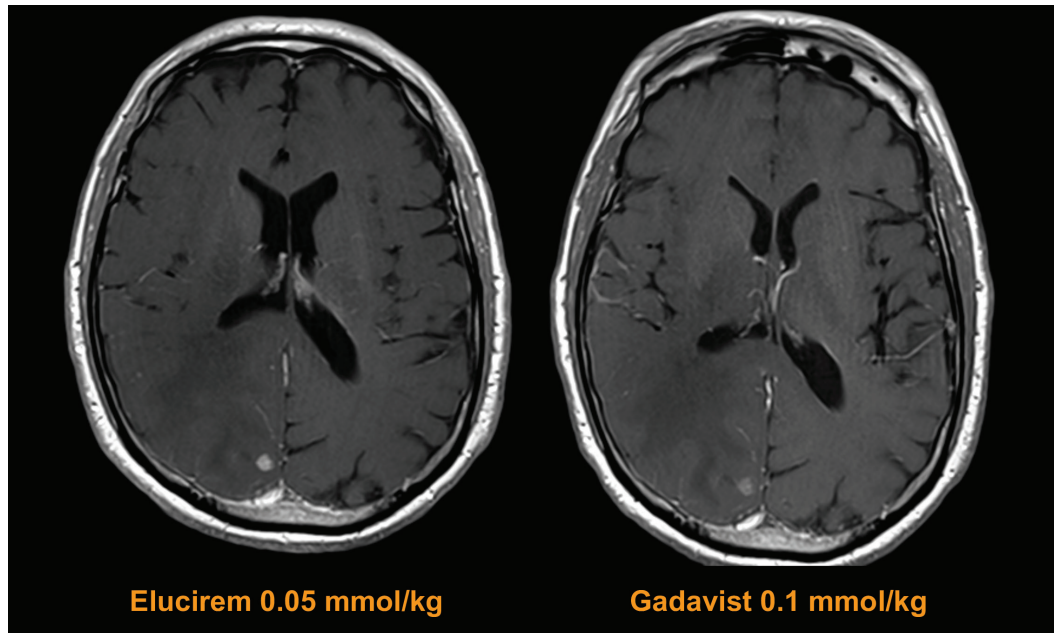
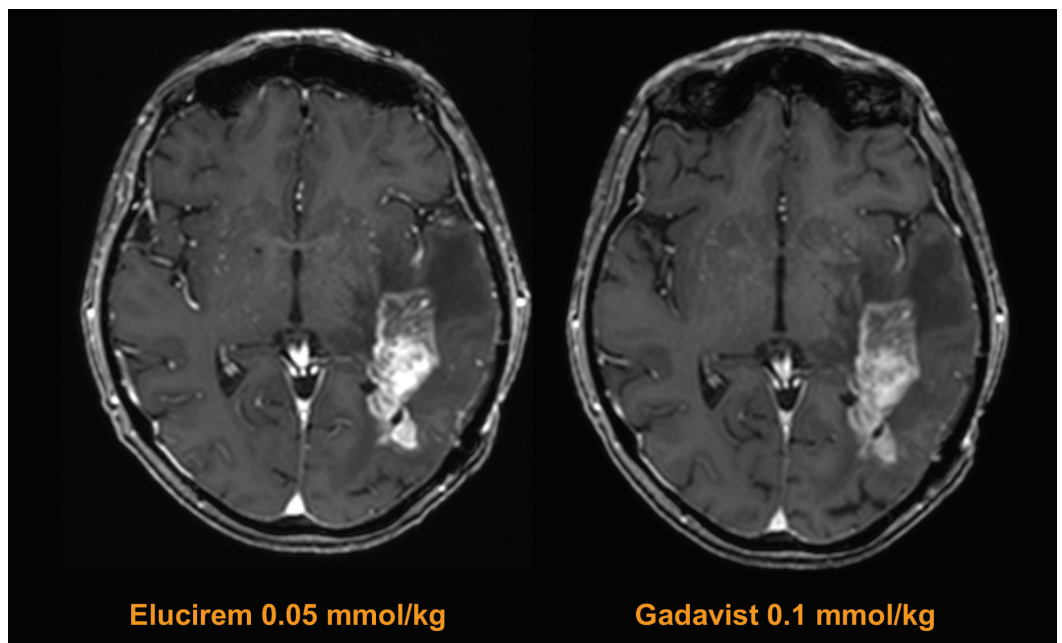


Figure 8. Matched pair of brain MR images from a 70-year-old female with high-grade glioma.⁵²



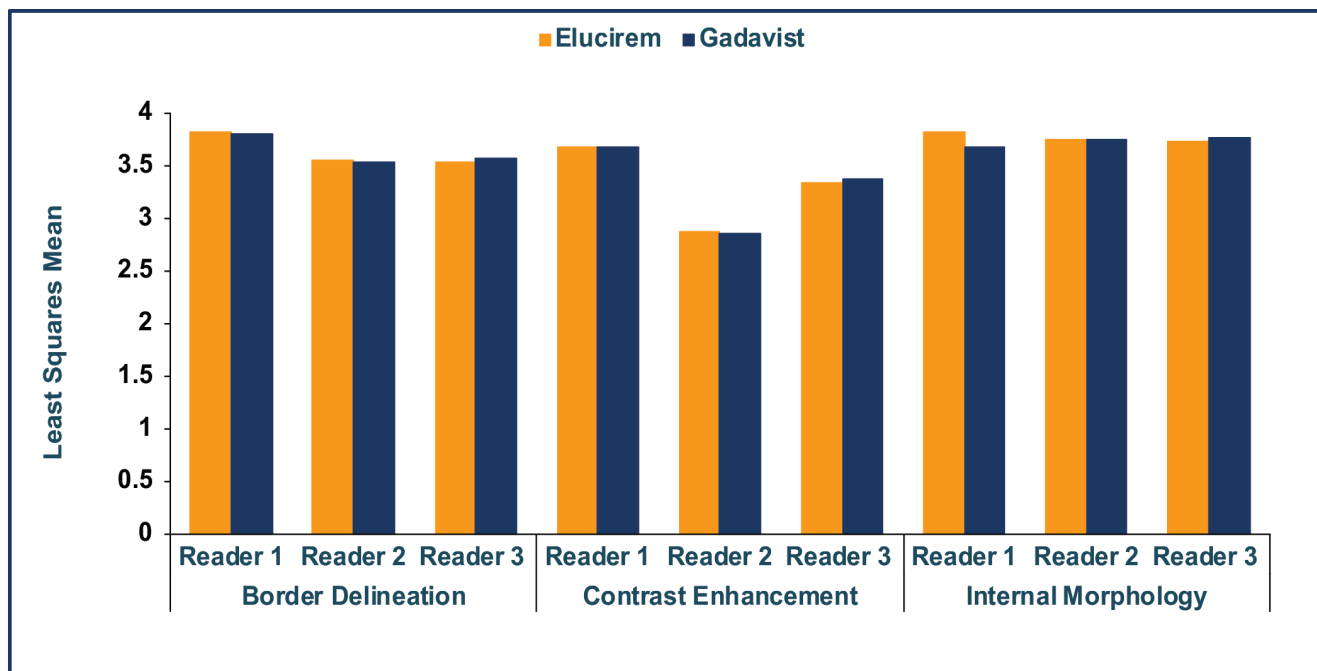
in certain specific applications. For example, contrast can be helpful for dynamic imaging of patients at increased risk for hepatocellular carcinoma (HCC) in the late arterial phase.⁵⁴ In addition, for breast imaging, it has been demonstrated that more lesions can be seen with a higher-relaxivity GBCA.³⁷ Notably, both patients at increased risk for

HCC and for breast cancer typically require frequent CE-MRI; therefore, the ability to use a macrocyclic, high-relaxivity agent such as Elucirem to obtain the enhancement needed at half the conventional dose of gadolinium will reduce a patient's exposure to Gd.

Another potential use for high-relaxivity, macrocyclic GBCAs

is in low magnetic field strength scanners. Such scanners are becoming more common and typically provide images with lower signal-to-noise ratios. Therefore, a high-relaxivity GBCA may, in part, compensate for the low signal noise for detection and visualization of lesions with abnormal vascularity. The sensitivity and specificity of

Figure 9. Comparison of lesion visualization between 0.05 mmol/kg Elucirem-enhanced and 0.1 mmol/kg Gadavist-enhanced paired body MR images demonstrating noninferiority of Elucirem (lower limit of the 95% CI of the difference above the noninferiority margin of -0.35 in all cases ($P < 0.0001$)).^{7,55}



Elucirem for detection of specific breast pathology are not known.

Elucirem Clinical Development Program for Body Imaging

As part of the phase 3 trials, gadopiclenol-enhanced images were compared to unenhanced images and to Gadavist-enhanced images for body MRI in 304 adults with suspected enhancing abnormalities in at least one body region: the head and neck, thorax, abdomen, pelvis, and musculoskeletal system (the PROMISE Trial; NCT03986138). The study design was similar to that of the PICTURE Trial. Three readers assessed images of the head and neck, three readers assessed images of the musculoskeletal system, and three readers assessed other areas collectively referred to as the body (thorax, abdomen, and pelvis).⁷ Similar to those in the PICTURE Trial, images enhanced with 0.05 mmol/kg gadopiclenol were significantly superior to

unenhanced images and noninferior to images enhanced with 0.1 mmol/kg Gadavist.^{7,55} (Figure 9)

Elucirem in Pediatric MR Imaging

The considerations for contrast use in pediatric patients are, in general, similar to those in adults but of potentially greater clinical concern. These patients often require surveillance imaging that, given their age, can result in multiple administrations over their lifetime.⁵⁶ To date, the only known adverse health effect related to gadolinium retention is the rare condition NSF that occurs in a small subgroup of patients with pre-existing kidney failure; the FDA continues to assess the health effects of Gd retention in the body.⁵⁷

The overall trend in pediatric imaging has been to avoid linear contrast agents in favor of macrocyclic agents.⁵⁸ The ability

to use half of the conventional dose of an agent with similar contrast enhancement and safety profile is likely to be hailed as a welcome development by pediatric radiologists.

The safety and effectiveness of Elucirem have not been established in pediatric patients younger than 2 years.

Conclusions

Elucirem is the first macrocyclic, high-relaxivity GBCA approved by the FDA. It was developed to address the concerns raised by the regulatory agency and medical associations. The approved dose of Elucirem is 0.05 mmol/kg, providing half the Gd of the other GBCAs but with no loss of signal. At this lower dose, Elucirem has shown to be noninferior to 0.1 mmol/kg of another macrocyclic GBCA, Gadavist. In summary, Elucirem has a unique combination

of properties (high relaxivity, high kinetic stability) that allows the agent to be used at half dose to reduce patient exposure to the toxic Gd ion.

References

- American College of Radiology (ACR) Committee on Drugs and Contrast Media. ACR Manual on Contrast Media, 2022. Available at: <https://www.acr.org/Clinical-Resources/Contrast-Manual>. Accessed December 19, 2022.
- Perazella MA, Rodby RA. Gadolinium-induced nephrogenic systemic fibrosis in patients with kidney disease. *Am J Med.* 2007;120:561-562.
- Food and Drug Administration (FDA) Website. Gadolinium Retention Following Gadolinium Based Contrast Agents MRIs: Brain and Other Organs. Available at: <https://www.fda.gov/media/107662/download>. Accessed January 25, 2023.
- Robic C, Port M, Rousseaux O, et al. Physicochemical and pharmacokinetic profiles of gadopiclenol: a new macrocyclic gadolinium chelate with high T1 relaxivity. *Invest Radiol.* 2019;54:475-484.
- Clariscan™ (gadoterate meglumine) [prescribing information]. Marlborough, MA: GE Healthcare Inc.; November, 2019.
- Dotarem® (gadoteric acid) [prescribing information]. Bloomington, IN: Guerbet LLC; April, 2022.
- Elucirem™ (gadopiclenol) [prescribing information]. Princeton, NJ: Guerbet LLC; October, 2022.
- Gadavist® (gadobutrol) injection [prescribing information]. Wayne, NJ; Bayer HealthCare Pharmaceuticals; April 2016.
- MultiHance® (gadobenate dimeglumine) injection [prescribing information]. Princeton, NJ; Bracco Diagnostics Inc.; July 2013.
- Omniscan™ (gadodiamide) injection [prescribing information]. Princeton, NJ: GE Healthcare; August 2013.
- ProHance® (Gadoteridol) Injection, [prescribing information]. Princeton, NJ: Bracco Diagnostics Inc.; November 2013.
- Vueway™ (gadopiclenol) [prescribing information]. Monroe Township, NJ; Bracco Diagnostics Inc.; September, 2022.
- Port M, Idée JM, Medina C, Robic C, Sabatou M, Corot C. Efficiency, thermodynamic and kinetic stability of marketed gadolinium chelates and their possible clinical consequences: a critical review. *Biomaterials.* 2008; 21:469-490.
- Idée JM, Port M, Robic C, Medina C, Sabatou M, Corot C. Role of thermodynamic and kinetic parameters in gadolinium chelate stability. *J Magn Reson Imaging.* 2009; 30:1249-1258.
- Thomsen HS, Marckmann P, Logager VB. Nephrogenic systemic fibrosis (NSF): a late adverse reaction to some of the gadolinium-based contrast agents. *Cancer Imaging.* 2007;7:130-137.
- Mathur M, Jones JR, Weinreb JC. Gadolinium deposition and nephrogenic systemic fibrosis: A radiologist's primer. *Radiographics.* 2020;40:153-162.
- White GW, Gibby WA, Tweedle MF. Comparison of Gd(DTPA-BMA) (Omniscan) versus Gd(HP-DO3A) (ProHance) relative to gadolinium retention in human bone tissue by inductively coupled plasma mass spectroscopy. *Invest Radiol.* 2006;41:272-278.
- Xia D, Davis RL, Crawford JA, Abraham JL. Gadolinium released from MR contrast agents is deposited in brain tumors: in situ demonstration using scanning electron microscopy with energy dispersive X-ray spectroscopy. *Acta Radiol.* 2010;51:1126-1136.
- Kanda T, Ishii K, Kawaguchi H, et al. High signal intensity in the dentate nucleus and globus pallidus on unenhanced T1-weighted MR images: relationship with increasing cumulative dose of a gadolinium-based contrast material. *Radiology.* 2014;270:834-841.
- Errante Y, Cirimele V, Mallio CA, Di Lazzaro V, Zobel BB, Quattrocchi CC. Progressive increase of T1 signal intensity of the dentate nucleus on unenhanced magnetic resonance images is associated with cumulative doses of intravenously administered gadodiamide in patients with normal renal function, suggesting dechelation. *Invest Radiol.* 2014;49:685-690.
- Radbruch A, Weberling LD, Kieslich PJ, et al. Gadolinium retention in the dentate nucleus and globus pallidus is dependent on the class of contrast agent. *Radiology.* 2015;275:783-791.
- Quattrocchi CC, Mallio CA, Errante Y, Beomonte Zobel B. High T1 signal intensity in dentate nucleus after multiple injections of linear gadolinium chelates. *Radiology.* 2015;276(2):616-617.
- Weberling LD, Kieslich PJ, Kickingreder P, et al. Increased signal intensity in the dentate nucleus on unenhanced T1-weighted images after gadobenate dimeglumine administration. *Invest Radiol.* 2015;50:743-748.
- McDonald RJ, McDonald JS, Kallmes DF, et al. Gadolinium Deposition in Human Brain Tissues after Contrast-enhanced MR Imaging in Adult Patients without Intracranial Abnormalities. *Radiology.* 2017;161595
- Kanal E, Maravilla K, Rowley HA. Gadolinium contrast agents for CNS imaging: current concepts and clinical evidence. *AJNR Am J Neuroradiol.* 2014;35:2215-2226.
- Greco A, Parker JR, Ratcliffe CG, Kirchin MA, McNamara MT. Phase III, randomized, double-blind, cross-over comparison of gadoteridol and gadopentetate dimeglumine in magnetic resonance imaging of patients with intracranial lesions. *Australas Radiol.* 2001;45:457-463.
- Anzalone N, Gerevini S, Scotti R, Vezzulli P, Picozzi P. Detection of cerebral metastases on magnetic resonance imaging: intraindividual comparison of gadobutrol with gadopentetate dimeglumine. *Acta Radiol.* 2009;50:933-940.
- Essig M, Tartaro A, Tartaglione T, Pirovano G, Kirchin MA, Spinazzi A. Enhancing lesions of the brain: intraindividual crossover comparison of contrast enhancement after gadobenate dimeglumine versus established gadolinium comparators. *Acad Radiol.* 2006;13:744-751.
- Colosimo C, Knopp MV, Barreau X, et al. A comparison of Gd-BOPTA and Gd-DOTA for contrast-enhanced MRI of intracranial tumours. *Neuroradiol.* 2004;46:655-665.
- Colosimo C, Ruscalleda J, Korves M, et al. Detection of intracranial metastases: a multicenter, inpatient comparison of gadobenate dimeglumine-enhanced MRI with routinely used contrast agents at equal dosage. *Invest Radiol.* 2001;36:72-81.
- Knopp MV, Runge VM, Essig M, et al. Primary and secondary brain tumors at MR imaging: bicentric intraindividual crossover comparison of gadobenate dimeglumine and gadopentetate dimeglumine. *Radiology.* 2004;230:55-64.
- Maravilla KR, Maldjian JA, Schmalfuss IM, et al. Contrast enhancement of central nervous system lesions: multicenter intraindividual crossover comparative study of two MR contrast agents. *Radiology.* 2006;240:389-400.
- Rowley HA, Scialfa G, Gao PY, et al. Contrast-enhanced MR imaging of brain lesions: a large scale intraindividual crossover comparison of gadobenate dimeglumine versus gadodiamide. *AJNR Am J Neuroradiol.* 2008;29:1684-1691.
- Rumboldt Z, Rowley HA, Steinberg F, et al. Multicenter, double-blind, randomized, intraindividual crossover comparison of gadobenate dimeglumine and gadopentetate dimeglumine in MRI of brain tumors at 3 Tesla. *J Magn Reson Imaging.* 2009;29:760-767.
- Seidl Z, Vymazal J, Mechl M, et al. Does higher gadolinium concentration play a role in the morphologic assessment of brain tumors? Results of a multicenter intraindividual crossover comparison of gadobutrol versus gadobenate dimeglumine (the MERIT study). *AJNR Am J Neuroradiol.* 2012;33:1050-1058.
- Vaneckova M, Herman M, Smith MP, et al. The benefits of high relaxivity for brain tumor imaging: results of a multicenter intraindividual crossover comparison of gadobenate dimeglumine with gadoterate meglumine (the BENEFIT study). *AJNR Am J Neuroradiol.* 2015;36:1589-1598.
- Martincich L, Faivre-Pierret M, Zechmann CM, et al. Multicenter, double-blind, randomized, intraindividual crossover comparison of gadobenate dimeglumine and gadopentetate dimeglumine for breast MR imaging (DETECT Trial). *Radiology.* 2011;258:396-408.
- Pediconi F, Catalano C, Padula S, et al. Contrast-enhanced MR mammography: improved lesion detection and differentiation with gadobenate dimeglumine. *AJR Am J Roentgenol.* 2008;191:1339-1346.
- Gerretsen SC, le Maire TF, Miller S, et al. Multicenter, double-blind, randomized, intraindividual crossover comparison of gadobenate dimeglumine and gadopentetate dimeglumine for MR angiography of peripheral arteries. *Radiology.* 2010;255:988-1000.
- Spampinato MV, Nguyen SA, Rumboldt Z. Comparison of gadobenate dimeglumine and gadodiamide in the evaluation of spinal vascular anatomy with MR angiography. *AJNR Am J Neuroradiol.* 2010;31:1151-1156.
- Schneider G, Maas R, Schultze Kool L, et al. Low-dose gadobenate dimeglumine versus standard dose gadopentetate dimeglumine for contrast-enhanced magnetic resonance imaging of the liver: an intra-individual crossover comparison. *Invest Radiol.* 2003;38:85-94.

- 42) Homayoon B, Diwakar H, Strovski E, et al. Half-dose gadobenate dimeglumine versus standard-dose gadodiamide in dynamic magnetic resonance imaging of non-cirrhotic livers: a retrospective intra-individual crossover comparison. *Abdom Imaging*. 2014;39:955-962.
- 43) Cheong BY, Duran C, Preventza OA, Muthupillai R. Comparison of low-dose higher-relaxivity and standard-dose lower-relaxivity contrast media for delayed-enhancement MRI: a blinded randomized crossover study. *AJR Am J Roentgenol*. 2015;205:533-539.
- 44) Clauser P, Helbich TH, Kapetas P, et al. Breast lesion detection and characterization with contrast-enhanced magnetic resonance imaging: Prospective randomized intraindividual comparison of gadoterate meglumine (0.15 mmol/kg) and gadobenate dimeglumine (0.075 mmol/kg) at 3T. *J Magn Reson Imaging*. 2019;49:1157-1165.
- 45) Wang J, Yan F, Liu J, et al. Multicenter, intra-individual comparison of single dose gadobenate dimeglumine and double dose gadopentetate dimeglumine for MR angiography of the peripheral arteries (the Peripheral VALUE Study). *J Magn Reson Imaging*. 2013;38:926-937.
- 46) Xing X, Zeng X, Li X, et al. Contrast-enhanced MR angiography: does a higher relaxivity MR contrast agent permit a reduction of the dose administered for routine vascular imaging applications? *Radiol Med*. 2015;120:239-250.
- 47) Li Y, Li X, Li D, et al. Multicenter, intraindividual comparison of single-dose gadobenate dimeglumine and double-dose gadopentetate dimeglumine for MR angiography of the supra-aortic arteries (the Supra-Aortic VALUE study). *AJNR Am J Neuroradiol*. 2013;34:847-854.
- 48) Gulani V, Calamante F, Shellock FG, Kanal E, Reeder SB; International Society for Magnetic Resonance in Medicine. Gadolinium deposition in the brain: summary of evidence and recommendations. *Lancet Neurol*. 2017;16:564-570.
- 49) McDonald JS, Hunt CH, Kolbe AB, et al. Acute adverse events following gadolinium-based contrast agent administration: a single-center retrospective study of 281 945 injections. *Radiology*. 2019;292:620-627.
- 50) Behzadi AH, Zhao Y, Farooq Z, Prince MR. Immediate allergic reactions to gadolinium-based contrast agents: a systematic review and meta-analysis. *Radiology*. 2018;286:471-482.
- 51) Bendszus M, Roberts D, Kolumban B, et al. Dose finding study of gadopiclenol, a new macrocyclic contrast agent, in MRI of central nervous system. *Invest Radiol*. 2020;55:129-137.
- 52) Guerbet Data on file: GDX-44-010 – The PICTURE trial: gadopiclenol in CNS MRI.
- 53) Loevner LA, Kolumban B, Hutóczki G, et al. Efficacy and safety of gadopiclenol for contrast-enhanced MRI of the central nervous system: The PICTURE Randomized Clinical Trial. *Invest Radiol*. 0:10.1097/RLI.0000000000000944, December 19, 2022.
- 54) Niendorf E, Spilseth B, Wang X, Taylor A. Contrast-enhanced MRI in the diagnosis of HCC. *Diagnostics (Basel)*. 2015;5:383-398.
- 55) Guerbet Data on file: GDX-44-011 – The PROMISE trial: gadopiclenol in Body MRI.
- 56) Roberts DR, Holden KR. Progressive increase of T1 signal intensity in the dentate nucleus and globus pallidus on unenhanced T1-weighted MR images in the pediatric brain exposed to multiple doses of gadolinium contrast. *Brain Dev*. 2016;38:331-336.
- 57) Food and Drug Administration (FDA) Website. FDA Drug Safety Communications. FDA warns that gadolinium-based contrast agents (GBCAs) are retained in the body; requires new class warnings. December 19, 2017. Available at: <https://www.fda.gov/media/109825/download>. Accessed January 25, 2023.
- 58) Mithal LB, Patel PS, Mithal D, Palac HL, Rozenfeld MN. Use of gadolinium-based magnetic resonance imaging contrast agents and awareness of brain gadolinium deposition among pediatric providers in North America. *Pediatr Radiol*. 2017; 47:657-664.

ELUCIREM™ (gadopiclenol) injection Important Safety Information

WARNING: NEPHROGENIC SYSTEMIC FIBROSIS (NSF)

See full prescribing information for complete boxed warning

Gadolinium-based contrast agents (GBCAs) increase the risk for NSF among patients with impaired elimination of the drugs. Avoid use of GBCAs in these patients unless the diagnostic information is essential and not available with non-contrast MRI or other modalities.

- The risk for NSF appears highest among patients with:
 - Chronic, severe kidney disease (GFR <30 mL/min/1.73 m²), or
 - Acute kidney injury.
- Screen patients for acute kidney injury and other conditions that may reduce renal function. For patients at risk for chronically reduced renal function (for example, age >60 years, hypertension or diabetes), estimate the glomerular filtration rate (GFR) through laboratory testing.

Indications and Usage

ELUCIREM™ (gadopiclenol) injection is indicated in adult and pediatric patients aged 2 years and older for use with magnetic resonance imaging (MRI) to detect and visualize lesions with abnormal vascularity in the central nervous system (brain, spine, and associated tissues), and the body (head and neck, thorax, abdomen, pelvis, and musculoskeletal system).

Contraindications

History of hypersensitivity reactions to ELUCIREM™

Warnings and Precautions

- Nephrogenic Systemic Fibrosis: GBCAs increase the risk for NSF among patients with impaired elimination of the drugs. Avoid use of GBCAs among these patients unless the diagnostic information is essential and not available with non-contrast MRI or other modalities. The GBCA-associated NSF risk appears highest for patients with chronic, severe kidney disease as well as patients with acute kidney injury.
- Hypersensitivity Reactions: With GBCAs, serious hypersensitivity reactions have occurred. In most cases, initial symptoms occurred within minutes of GBCA administration and resolved with prompt emergency treatment. Before ELUCIREM administration, assess all patients for any history of a reaction to contrast media, bronchial asthma and/or allergic disorders. These patients may have an increased risk for a hypersensitivity reaction to ELUCIREM.
- Gadolinium Retention: Gadolinium is retained for months or years in several organs. Linear GBCAs cause more retention than macrocyclic GBCAs. Consequences of gadolinium retention in the brain have not been established. Pathologic and clinical consequences of GBCA administration and retention in skin and other organs have been established in patients with impaired renal function. While clinical consequences of gadolinium retention have not been established in patients with normal renal function, certain patients might be at higher risk. These include patients requiring multiple lifetime doses, pregnant and pediatric patients, and patients with inflammatory conditions. Consider the retention characteristics of the agent when choosing a GBCA for these patients. Minimize repetitive GBCA imaging studies, particularly closely spaced studies when possible

- **Acute Kidney Injury:** In patients with chronically reduced renal function, acute kidney injury requiring dialysis has occurred with the use of GBCAs. The risk of acute kidney injury may increase with increasing dose of the contrast agent. Do not exceed the recommended dose.
- **Extravasation and Injection Site Reactions:** Injection site reactions such as injection site pain have been reported in the clinical studies with ELUCIREM. Extravasation during ELUCIREM administration may result in tissue irritation. Ensure catheter and venous patency before the injection of ELUCIREM.
- **Interference with Visualization of Lesions Visible with Non-Contrast MRI:** As with any GBCA, ELUCIREM may impair the visualization of lesions seen on non-contrast MRI. Therefore, caution should be exercised when Gadopiclenol MRI scans are interpreted without a companion non-contrast MRI scan.

Adverse Reactions:

In clinical trials, the most frequent adverse reactions that occurred in > 0.2% of patients who received ELUCIREM included: injection site pain, headache, nausea, injection site warmth, injection site coldness, dizziness, and localized swelling

Adverse reactions that occurred with a frequency \leq 0.2% in patients who received 0.05 mmol/kg BW ELUCIREM included: maculopapular rash, vomiting, worsened renal impairment, feeling hot, pyrexia, oral paresthesia, dysgeusia, diarrhea, pruritus, allergic dermatitis, erythema, injection site paresthesia, Cystatin C increase, and blood creatinine increase.

Use in Specific Populations

- **Pregnancy:** GBCAs cross the human placenta and result in fetal exposure and gadolinium retention. There are no available data on ELUCIREM use in pregnant women to evaluate for a drug-associated risk of major birth defects, miscarriage or other adverse maternal or fetal outcomes.
- **Lactation:** There are no data on the presence of ELUCIREM in human milk, the effects on the breastfed infant, or the effects on milk production. However, published lactation data on other GBCAs indicate that 0.01 to 0.04% of the maternal gadolinium dose is excreted in breast milk.
- **Pediatric Use:** The safety and effectiveness of ELUCIREM have not been established in pediatric patients younger than 2 years of age.
- **Geriatric Use:** This drug is known to be substantially excreted by the kidney, and the risk of adverse reactions to this drug may be greater in patients with impaired renal function.
- **Renal Impairment:** In patients with renal impairment, the exposure of gadopiclenol is increased compared to patients with normal renal function. This may increase the risk of adverse reactions such as nephrogenic systemic fibrosis (NSF). Avoid use of GBCAs among these patients unless the diagnostic information is essential and not available with non-contrast MRI or other modalities. No dose adjustment of ELUCIREM is recommended for patients with renal impairment. ELUCIREM can be removed from the body by hemodialysis

You are encouraged to report negative side effects of prescription drugs to the FDA.

Visit www.fda.gov/medwatch or call 1-800-FDA-1088.

Please see the full Prescribing Information, including the Medication Guide, for additional important safety information.

